



Can Local Anesthesia Prevent the Injury of Brachial Plexus?

Lokal Anestezi Brakial Pleksusun Hasarını Engelleyebilir mi?

Schwannoma Arising From Brachial Plexus

Alaattin Öztürk, Ergun Uçmaklı, Memduh Kerman
Fatih Üniversitesi Sema Hastanesi, İstanbul, Türkiye

Özet

Schwannomlar (nörolemmoma) periferik sinir kılıfından kaynaklanan benign tümörlerdir. Vücudun her yerinde görülürler ama olgularının yaklaşık yarısı baş-boyun bölgesinde yerleşir. Brakiyal pleksus kaynaklı schwannomlar boyun kitlelerinin nadir bir nedenidir. Bu yüzden ameliyat öncesi seyrek olarak teşhis edilirler. Genel anestezi ile eksizyonları sonrası sinir hasarı gelişme riski fazladır. Yazımızda brakiyal pleksus kaynaklı schwannom olgusu sunulmuş ve lokal anestezi ile eksizyonun sinir hasarını engelleyebileceği gösterilmiştir.

Anahtar Kelimeler

Schwannoma; Lokal Anestezi; Komplikasyon

Abstract

Schwannomas (neurilemmomas) are benign tumors arising from peripheral nerve sheaths. They can be seen all over the body, but approximately half of the cases occur in the head and neck region. The schwannoma arising from brachial plexus is a rare cause of neck masses. They are rarely diagnosed preoperatively. The risk of nerve damage after excision is high under general anesthesia. In this article, a case of brachial plexus schwannoma was presented and the excision with local anesthesia was shown to prevent the nerve injury.

Keywords

Schwannoma; Local Anesthesia; Complication

DOI: 10.4328/JCAM.1326

Received: 17.10.2012 Accepted: 31.10.2012 Printed: 01.03.2016

J Clin Anal Med 2016;7(2): 244-6

Corresponding Author: Alaattin Öztürk, Fatih Üniversitesi Sema Hastanesi, Yalı Mh. Sahilyolu Sk. No.16, 34844 Maltepe, İstanbul, Türkiye.

T.: +90 2164589000 F.: +90 2163834972 E-Mail: aloz1969@yahoo.com

Introduction

Schwannomas, which originate from Schwann cells surrounding peripheral motor, sensory, cranial and autonomic nerves in almost all over the human body, are solid and benign tumors. The 25-40% of all schwannoma cases occur in the head and neck [1]. The incidence is higher in the fourth decade but it can be seen at any age. The schwannomas of the neck commonly originate from vagus nerve and they are placed in parapharyngeal space [2]. In addition, they are derived from sympathetic chain, the cervical plexus and brachial plexus. The morbidities due to nerve damage often develop because the excision of schwannoma was usually performed under general anesthesia [3;4]. Excision of lesions under local anesthesia has a role in determining its connection to the nerves and can help prevent nerve damage. Excision by local anesthesia prevented possible nerve damage in our case.

Case Report

A 35-year-old male patient applied to internal medicine for a neck mass. The patient was referred to surgery for excisional biopsy of the mass for possible metastatic lymphadenopathy. By physical examination a 4x2 cm smooth, painless, hard and mobile mass was detected in the left supraclavicular area. Laboratory analysis showed normal values of hemogram and erythrocyte sedimentation rate. Ultrasonography of the neck revealed a hypoechoic solid mass of 42x29x23mm size and was evaluated as lymphadenopathy. In addition, two nodules (8 and 5 mm in size) were detected in the thyroid gland. Excision under local anesthesia of the mass was decided because it was mobile and superficial.

Incision was done over the mass according to skin lines under local anesthesia. Electrocautery was used for hemostasis during excision. Muscle contractions in the patient's left arm were observed due to electrical stimulation. The mass was separated from the surrounding tissue with its external capsule. However, the mass was attached from both ends with fibro-vascular bands. These bands which have been considered as lymph channels and blood vessels were isolated and tracked by finger. At that moment, the patient complained of numbness and loss of power in his left hand. For this reason the surgical procedure was stopped and a neurosurgery consultation was requested. The mass was thought to be originated from brachial plexus and bands that seen were bundle of nerves. To prevent nerve injury, the capsule was opened and the mass was enucleated (Figure 1). Pathologic examination of the mass revealed a diagnosis of schwannoma (Figure 2). At the neurological examination after the surgery, there was no sign of sensory and motor loss of the patient's left arm.

Discussion

Schwannomas are rare benign tumors of the head and neck. They can be seen at any age but most commonly in the third and fourth decades [3]. The 25-40% of all schwannomas occurs in the head and neck [1]. Schwannomas exist often in parapharyngeal space in the neck and arise most commonly from the vagus nerve [3]. Schwannomas arising from vagus appear usually as a midline neck mass; and those from the cervical and brachial plexus as lateral neck masses [5]. On a published series of 20

patients by Arajuo and colleagues, it was reported that 35% of schwannomas of the neck arose from vagus, 20% from the sympathetic chain, 20% from brachial plexus, 15% from cervical plexus, 5% from hypoglossal nerves and 5% from the lingual nerve. The mass in our patient was on the lateral side of the neck.

Schwannomas may rarely have malignant transformation but in a study carried out in a reference hospital, the rate was found to be as high as 14.2% [4].

The neck schwannomas usually appear as painless, firm solitary mass, and rarely as a cystic mass [6]. The mass in our patient was painless and solid. Schwannomas are neoplasms which grow slowly. Zhang and colleagues reported a growth rate of 5.5 cm in 20 years in one of the patients who refused surgical treatment [7].

Neurologic deficits are very rare during the diagnosis. The possibility of the occurrence of the compression symptoms, pain and neurological deficits increases as the mass grows. Neurological deficits including the lower cranial nerve palsies, dysphagia, voice changes, Horner's syndrome and arm paralysis can be observed.

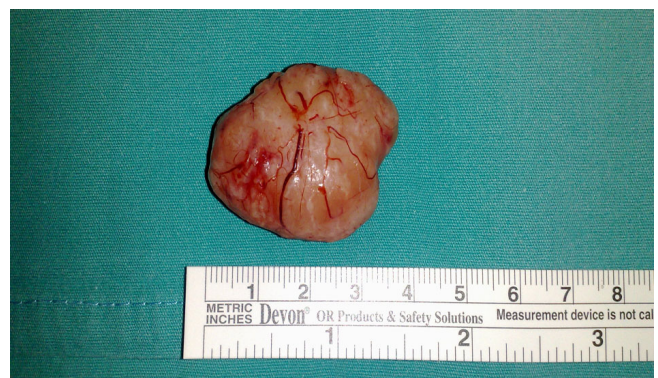

Figure 1. The mass (schwannoma) is seen after removal.

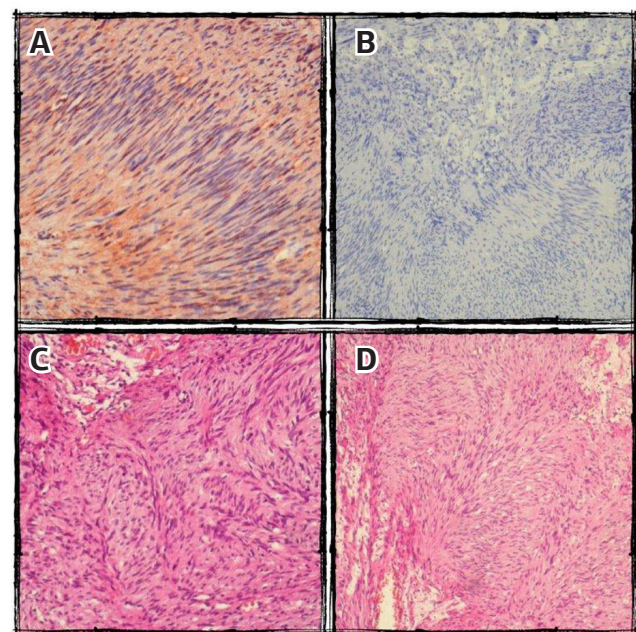


Figure 2. Histological findings of the excised specimen are seen. (staining, × enlargement) Schwann cells in a palisading pattern. (S100,×200)(A), Antoni A and Antoni B areas. (Synaptin, ×100)(B), Spindle-shaped cells in a palisading pattern (Antoni A) and the looser stromal areas of Antoni B. (Hematoxylin and Eosin, ×100)(C), Antoni A and Antoni B areas. (Hematoxylin and Eosin, ×200)(D).

Imaging modalities such as ultrasonography, tomography, magnetic resonance imaging and angiography can be used for diagnosis of the cases. Even though fine needle aspiration biopsy (FNAB) is recommended preoperatively, diagnosis of schwannoma cannot always be made [4]. Despite all these methods, these kinds of tumors can be usually diagnosed via surgical operation. Since the mass in the patient was excised with a prediagnosis of lymphadenopathy, FNAB and other examination methods were not needed.

Histopathological biphasic pattern was shown. Antoni A pattern consist of fuciform cells which have a long nucleus and form sequential fascicles and strips. Antoni B pattern is a hypocellular area which has a poor myxoid matrix and a few number of fusiform cells. Oval acellular areas surrounded by parallel nuclei, also known as Verocay body, can be observed.

Differential diagnoses of these patients include neurofibroma, brachial cyst, lipoma, angioma, lymphadenopathy, paraganglioma, rhabdomyoma, meningioma, and other neurogenic tumors. The treatment of schwannomas is surgical excision, and intracapsular enucleation is generally sufficient. The morbidity due to nerve damage after the excision is quite high. Horner syndrome is the most common complication [4]. Valentino and colleague [8] reported the percentage of successful surgical operations as 56%. In order to reduce the complication rate, intraoperative electrophysiological monitorization can be performed.

Since schwannoma surgeries are carried out under general anesthesia, nerve damage can only be identified after the surgery. Since we performed the surgery under local anesthesia, numbness in the right arm stated by the patient turned the excision into an intracapsular enucleation method and prevented possible nerve damage.

Recurrence after schwannoma excision is rare, and malignancy should be suspected in recurrent cases [3;4].

As a result, if the condition of the patient and the mass is suitable, local anesthesia can be a proper anesthesia method in order to avoid postoperative neurological sequels.

Competing interests

The authors declare that they have no competing interests.

References

1. Knight DM, Birch R, Pringle J. Benign solitary schwannomas: a review of 234 cases. *J Bone Joint Surg Br.* 2007;89(3):382-7.
2. Moukarbel RV, Sabri AN. Current management of head and neck schwannomas. *Curr Opin Otolaryngol Head Neck Surg* 2005;13:117-22.
3. de Araujo CE, Ramos DM, Moyses RA, Durazzo MD, Cernea CR, Ferraz AR. Neck nevire trunks schwannomas: Clinical features and postoperative neurologic outcome. *Laryngoscope* 2008;118:1579-82.
4. Langner E, Del Negro A, Akashi HK, Araujo PP, Tincani AJ, Martins AS. Schwannomas in the head and neck: retrospective analysis of 21 patients and review of the literature. *Sao Paulo Med J.* 2007;125(4):220-2.
5. Capparpur C, Büyüklü F, Çakmak İ, Öztop L, Özlüoğlu LN. Servikal sempatik zincirden kaynaklanan schwannom: Olgu sunumu. *Türk Otolaringoloji Arşivi* 2002;40:153-6.
6. Chen F, Miyahara R, Matsunaga Y, Koyama T. Schwannoma of the brachial plexus presenting as an enlarging cystic mass: Report of a case. *Thorac Cardiovasc Surg* 2008;14: 311-3.
7. Zhang H, Cai C, Wang S, Liu H, Ye Y, Chen X. Extracranial head and neck schwannomas: A clinical analysis of 33 patients. *Laryngoscope* 2007;117:278-81.
8. Valentino J, Boggess MA, Ellis JL, Hester TO, Jones RO. Expected neurologic outcomes for surgical treatment of cervical neurilemmomas. *Laryngoscope* 1998;108:1009-23.

How to cite this article:

Öztürk A, Uçmaklı E, Kerman M. Can Local Anesthesia Prevent the Injury of Brachial Plexus? *J Clin Anal Med* 2016;7(2): 244-6.